



Correlation of the Nerves Number at Three Points Exposed by Laser with Gonadal Maturation of Abalone (*Haliotis squamata*)

Dewa Ayu Angga Pebriani*, Maheno Sri Widodo and Abdul Rahem Faqih

Fisheries and Marine Science Faculty, University of Brawijaya, Indonesia

*Corresponding author's e-mail: pebridewayu@gmail.com

ABSTRACT: Abalone is one of marine commodities which possess high economic value. The demand on abalone in international markets rises every year. Therefore, efforts to improve abalone production are conducted and one of them is by applying laser puncture technology. The purpose of this research is to locate the best point for laser exposure which is based on the nerves distribution in three gonadal parts. Laser exposures were conducted in a home scaled hatchery in Musi Village, Bali. Gonadal tissue preparation was done in Laboratory of Medical Anatomy and Physiology of Medical Faculty, Universitas Brawijaya. The research used descriptive method to see the correlation of the numbers of nerves in three parts of gonads with the speed of abalone gonadal maturation by laser exposures. Variables observed were Gonadal Maturation Stages, Gonado Somatic Index (GSI) and gonadal histology of male and female abalone. The result showed that the best exposure for male abalone was done in posterior part while the mid interior part was best for female abalone.

Key words: Gonad Abalone, Laserpuncture, Oocyte, Nerves, Sperm

ORIGINAL ARTICLE
 PII: S225199391500018-5
 Received 09 May 2015
 Accepted 13 Jun 2015

INTRODUCTION

Abalone is classified as animals with exotic and high economic value. Living *H. asinina* can be sold at Rp 200,000/kg, and other species *H. squamata* at Rp 600,000/kg [1]. *H. squamata* is one of abalone type which is bred and sold at international markets. High demand of abalones makes abalone cultivation is needed and improved even more to meet the need of global markets.

Aquaculture of abalone is still being developed to meet the increasing market demand in the world. This farming activities has good development prospects in the future due to various considerations such simple farming techniques and the presence of feed still abound [2].

It is very important to be considered in the management of aquaculture activities is the parent of abalone. One way to get the parent with the optimal level of maturity gonad through laserpunktur technology. Laserpunktur technology has been shown to accelerate the process of growth, an increase in gonadal maturation, spawning accelerate and shorten the reproductive cycle of some species [3].

Problems exist in the cultivation of abalone are in its breeding phase. Abalone needs a long time to reach gonadal maturation and ready to spawn. Therefore, a new technique to fasten abalone's gonadal maturation is needed. Laserpuncture technology is one way to fasten gonadal maturation of abalone.

MATERIAL AND METHODS

Research was conducted from September 2014 to February 2015 in Musi, Buleleng District, Bali. Gonadal histology observation was conducted in Laboratory of Anatomy, Medical Faculty, Universitas Brawijaya and Laboratory of Fishery Products Safety, Faculty Fisheries and Marine Sciences, Brawijaya University. Treatment K was the control treatment (without laser exposure); treatment A was exposing laser to anterior part; treatment B was exposing laser to mid anterior part; and treatment C was exposing laser to posterior part. Abalone used was parent abalone 5-6 cm in size acquired by catching in the nature. Steps conducted were parent selection, acclimatization, laser exposure, and keeping period for a month. Variables observed in the research were Gonadal Maturation Stages, Gonad Somatic Index (GSI) and gonadal histology of male and female abalone. The number of nerves distribution can be found out by nitrate silver staining method, while preparation to see abalone's maturity microscopically was done by HE (Hematoxylin Eosin) staining method. GSI calculation was done by measuring the weight of abalone's body and its gonad.

RESULTS AND DISCUSSION

Figure 1 showed that the most nerve fibers for male abalone found in the posterior part with 45% percentage, while Figure 2 showed the most nerve fibers for female abalone were in mid anterior part with 54% percentage. These results explained the different of most nerve distribution in numbers between male and female abalone. Nerve distribution results were used as the base to explain the effect of laser exposure on gonadal maturation speed of male and female abalone.

Based on the histology of three abalone's gonadal parts, the results were as follows:




Figure 1. The number of nerve fibers in male abalone's gonad (A: anterior (30%); B: mid anterior (25%); C: posterior (45%))

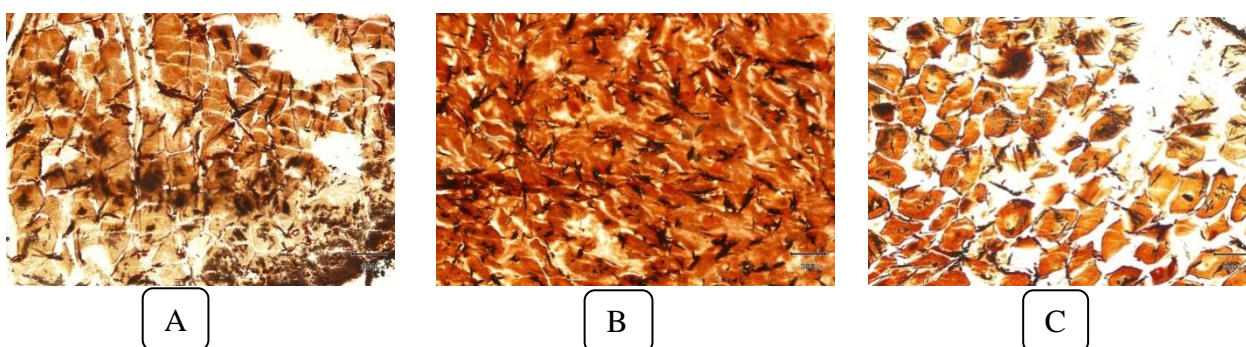


Figure 2. The number of nerve fibers in female abalone's gonad (A: anterior (22%); B: mid anterior (54%); C: posterior (24%))

Laser exposure was done to three target points, they are anterior, mid anterior, and posterior parts. Then abalone was kept for a month and observed for its gonadal growth. Results acquired from the laser exposure to abalone's gonadal maturation stages can be seen in Figure 3. Male abalone's gonad was cream-colored while the female's was green [2]. Condition of both male and female gonads before laser exposure was the same, at stage 1 for maturity.



Figure 3. Male abalone's maturation stages (K: Control; A: Laser exposure to anterior part; B: Laser exposure to mid anterior part; C: Laser exposure to posterior part)

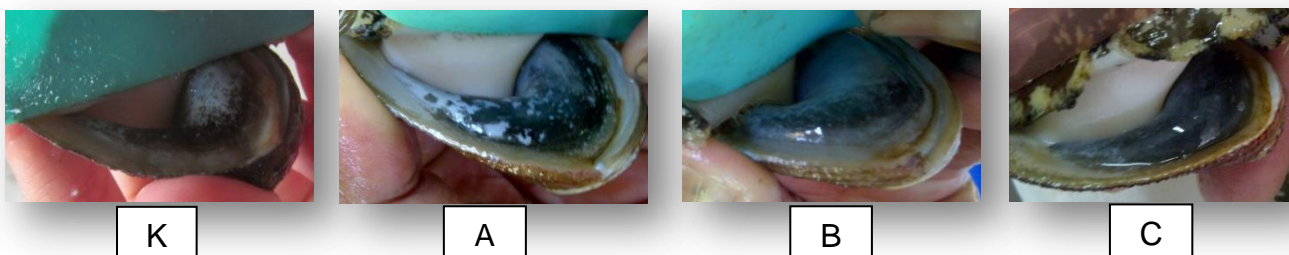


Figure 4. Female abalone's maturation stages (K: Control; A: Laser exposure to anterior part; B: Laser exposure to mid anterior part; C: Laser exposure to posterior part)

Figure 3 showed visual observation results to male abalone and it was noticed that male abalone's gonad which was not exposed to laser was still in stage 1 of maturity and abalone's gonads which were exposed to laser had grown with most growth was in treatment C where laser was exposed to posterior part. Abalone's gonad with treatment C was in stage 3 with

VGB percentage >50%, and with this condition gonad can be determined as fully matured [4]. Figure 4 showed visual observation results of female abalone after being exposed to laser and kept for a month. The biggest volume of gonad was from treatment B where was exposed to mid anterior part. Different volume of gonads can be seen between control treatment which was without laser exposure and treatments with laser exposure.

These different results were there because laserpuncture is an electromagnetic wave which can inhibit and biostimulate biological tissue, such as improving cellular activities, nervous regeneration, central or peripheral, and also taking roles in hormones and enzymes production [5]. That statement is enough to explain that abalone's maturation escalation was caused by stimulation from laser exposure which caused biostimulation to gonadal tissue. Impulse in the form of laser is delivered by nervous system to visceral ganglia as the center of induction [6] which is in the gonad so reproduction hormones can be produced and triggered the male and female abalone's growth. Stated that the more receptors, the faster response will be given [7]. Observation of gonad maturation can be done microscopically by abalone's gonadal histology test. Figure 5 showed that gonad's condition from treatment C reached maturation stage 3 because tubulus seminiferus was full of spermatozoa.

Figure 6 showed that gonad's condition from treatment B reached stage 3 with much more secondary oocytes than other gonad's treatment. More secondary oocytes showed that gonad is matured and ready for spawning. Based on male and female abalone's GSI calculation, there was the highest increase on the male abalone's maturation stage percentage from treatment C about 46,6%, while on female abalone GSI increase seen from treatment B about 45,53%. Male abalone's maturation stage percentage increase was higher than female abalone. It meant that male abalone gonadal growth was faster than compared to female abalone. This was because during oogenesis, abalone needs longer time and better nutrition [8]. Sex difference will cause different value on GSI. Generally, the higher GSI value, the heavier the gonad and the more matured oocytes. GSI value is closely related to yolk content in the oocyte, where the higher GSI value, the more matured oocytes in the ovary [9].

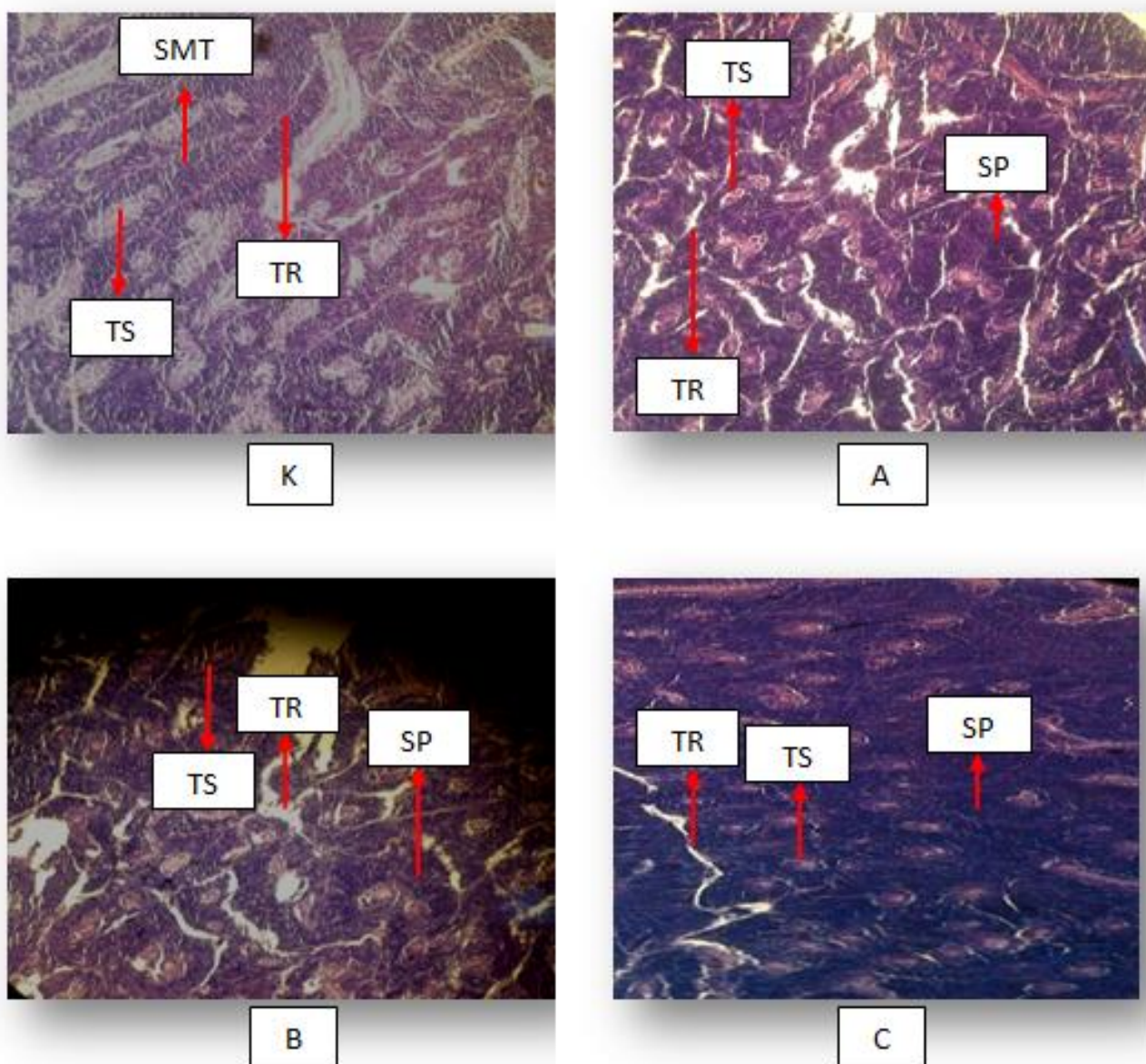


Figure 5. Result of histology test on male abalone's gonad (TR: Trabeculae; TS: TubulusSeminiferus; SMT (Spermatogonia); SP (Spermatozoa)

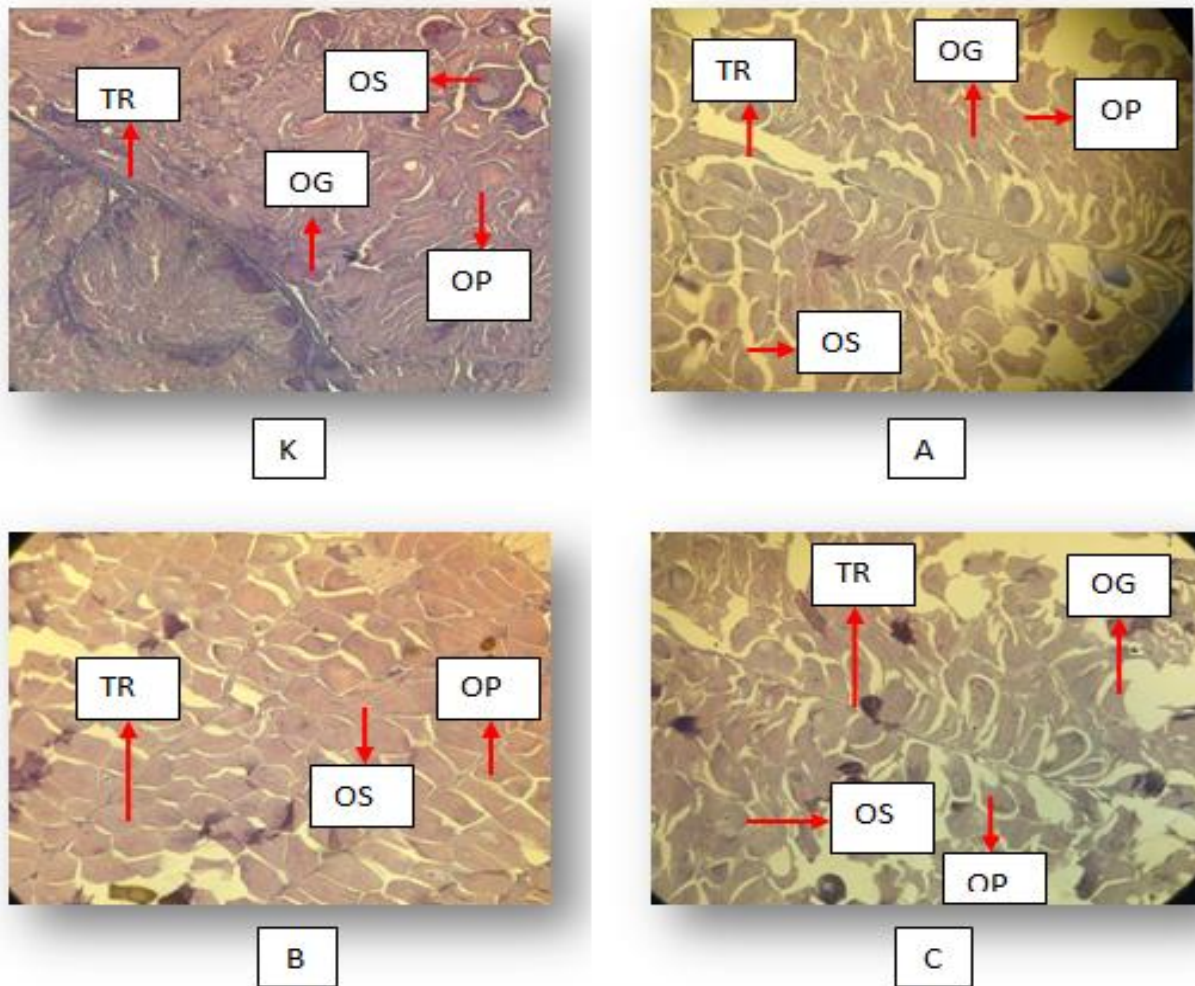


Figure 6. Result of histology test on female abalone's gonad (TR:Trabeculae; OG:Oogonia; OP: Primary Oocyte; OS: Secondary Oocyte)

CONCLUSION

Laser exposure give effect to the development of male and female gonad abalone. It happens because laser gives biostimulation to gonad's tissue, retrieved by the nerves and delivered to visceral ganglia to start reproduction hormones secretion which then improves male and female abalone's maturation. Laser exposure to male abalone is best conducted in the gonad's posterior part, while to female abalone is best conducted in the gonad's mid anterior part.

For recommendation the existence of further research on the effect of exposure to the laser beam on the quality of the resulting larvae. Beside that technology laserpunktur needs to be applied to other species.

REFERENCES

1. Susanto, B., I. Rusdi, R. Rahmawati, A. Giri, T. Sutarmat. 2010. Aplikasi Teknologi Pembesaran Abalon (*Haliotis squamata*) dalam Menunjang Pemberdayaan Masyarakat Pesisir. Prosiding Forum Inovasi Teknologi Akuakultur. Balai Besar Riset Perikanan Budidaya Laut Gondol. Bali. p:295-305.
2. Rusdi, I., B. Susanto, R. Rahmawati, A. Giri. 2011. Petunjuk Teknis Perbenihan Abalon, *Haliotis squamata*. Balai Besar Penelitian dan Pengembangan Budidaya Laut. Gondol, Bali.
3. Kusuma, P.S.W., Dyah H., Akhmad T.M., Woro H.S. 2008. Penyediaan broodstock ikan lele (*Clarias gariepinus*) menggunakan teknologi laserpunktur sebagai upaya penyediaan benih skala massal. Jurnal Litbang Provinsi Jawa Tengah 6(2):139-146.
4. Suminto, D. A. P. Sani, T. Susilowati. 2010. Prosentase Perbedaan Pengaruh Tingkat Kematangan Gonad terhadap Fertilitas dan Daya Tetas Telur dalam Pembentukan Buatan Abalon (*Haliotis asinina*). Jurnal Saintek Perikanan. 6(1): 79-87.

5. Kert, J dan Rose. 1989. Low laser therapy. Scandinavian Medical Laser Technology. London.
6. Hahn, K.O. 1990. Neurosecretory Staining in the Cerebral and Pleural-Pedal Ganglia of *Haliotis discus hannai* and *Trochus niloticus*, and it's Relationship to Reproduction. PhD thesis (Ed, by Sheperd, S.A., M.J. Tegnerdan S.A. Guzman). University of California, Davis.
7. Amtyaz, Khan M. A., Khan M. Z., dan Hashmi U.A. 2013. Studies of Gonadosomatic Index & Stages of Gonadal Development of Stiped piggy fish, *Pomadasystridens* (Family; *Pomadasyidae*) of Karachi Coast, Pakistan. *Journal of Entomology and Zoology Studies*. 1(5):28-31.
8. Riani, E. 2001. Peningkatan daya guna induk udang windu (*Penaeusmonodon* Fab.) afkir melalui pemberian dopamine serta modifikasinya dengan estradiol dan vitamin. Disertasi. Program Pascasarjana. Intstitut Pertanian Bogor, Bogor.
9. Bandpei, A, Mashor M.A.M., Andolmaleki S.H., Najafpour S.H., Bani A., Pourgholam R., Fazli H., Nasrolahzedah H dan Janbza A.A. 2011. The environmental of effect on spawning time, length at maturity and fecundity of Kutum (*Rutilus frisii kutum*) in Southern Part of Caspian Sea, Iran.*Iranica Journal of Energy & Environmental*. 2(4): 374-381